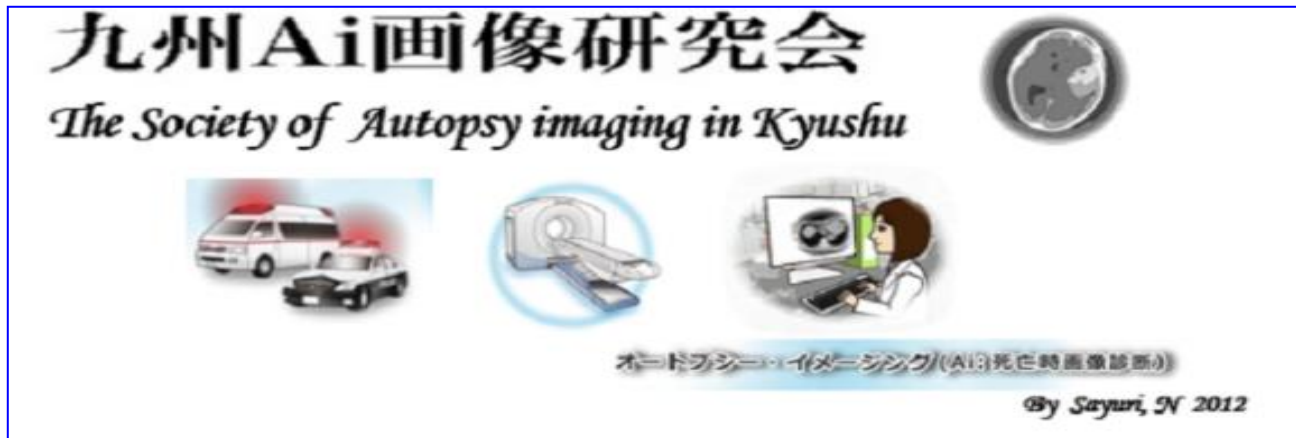



The 7thConference of the Society of Autopsy imaging in Kyushu

Dear Colleagues

We will like to extend our sincere gratitude to you for your continued encouragement. We are planning to organize the 7thConference of the Society of Autopsy imaging in Kyushu. Autopsy imaging is expected to play a significant role in investigating the cause of death. Our study aims to share the latest information about X-ray imaging, computed tomography, magnetic resonance imaging, 3 dimensional image processing technique, and case reports for Autopsy imaging. Thank you for your attendance.

Best regards

18 January, 2018

The Society of Autopsy imaging in Kyushu

Representative of the conference Kazuyuki Abe



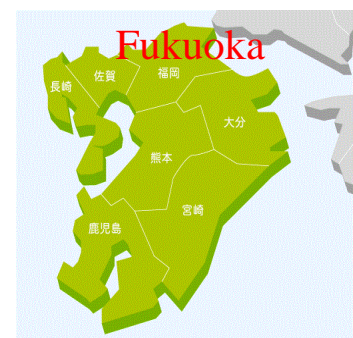
Date : 17 March 2018 (Saturday)

Time : 13:00 – 17:00

Venue : Kyushu University Hospital
Fukuoka

Room : Clinical small auditorium I

Entry fee: **1,000 yen**



<https://www.facebook.com/ai.kyusyu>

— **Program** — Moderator: Takashi Nakatomi

13:00-13:05 **Opening address : Kazuyuki Abe, PhD.**

13:05-13:35 [session1: Presentations by students] Chairman: Yuichi Shirakawa

The Ai education which students want to be

Junshingakuen University Tsuyoshi Kobayashi

The effect of shielding in terms of postmortem CT

Junshingakuen University Yosuke Kamimura

13:35-14:05 [session2: presentation by prizewinner at the 15th Annual Congress of Japan Society of Autopsy imaging]

Chairman: Hidekazu Kanayama

Correlation between intravascular gas on postmortem computed tomography and blood gas analysis

Shin Komonji Hospital Tomoaki Hagita

14:05-14:55 [session3: Presentation by president of the 16th Annual Congress of Japan Society of Autopsy imaging]

Chairman: Taiki Nakagawa

The Roles and future of postmortem MRI

Tsukuba Medical Center Hospital Tomoya Kobayashi

15:10-15:50 [session4: Special lecture by professional]

Chairman: Tomoaki Hagita

Checkpoint of Ai-CT diagnostic images useful for radiology technologists

Autopsy imaging Information center Seiji Yamamoto, MD, PhD.

15:50-17:00 [session5: Lectures for image reading]

Chairman: Manabu Ogata

What can we learn from these image findings?

Case report 1

NHO Kyushu Medical Center Daichi Ideguchi

Case report 2

Shimane University Hospital Yuki Ishida

Commentator: Seiji Yamamoto, MD, PhD.